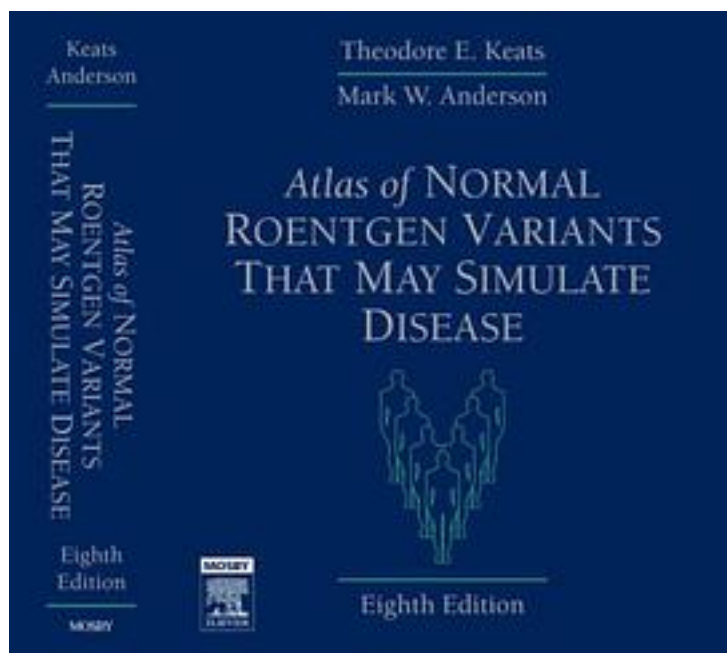


正常X线变异与可疑疾病鉴别诊断图谱



[正常X线变异与可疑疾病鉴别诊断图谱_下载链接1](#)

著者:Keats, Theodore E./ Anderson, Mark W., M.D.

出版者:Elsevier Science Health Science div

出版时间:2006-11

装帧:HRD

isbn:9780323043007

Get the latest update to a classic book that has proven invaluable for differentiating a normal image from a disease entity. For years, radiologists and residents as well as allied health professionals, have used this book to avoid false positives. Incorporating nearly 6000 images, this reference shows you more variants and pseudo-legions than any other text. This new edition contains over 300 new common and rare entities and hundreds of new MR and CT correlations to help you make the correct diagnosis. This bible of radiology now has a fresh, modern format and incorporates the latest cutting edge imaging techniques.

Helps you recognize normal anatomy as represented by imaging variants.

Includes all body systems.

Presents Over 6000 images, the largest collection in print.

Prepares you for pitfalls on the oral exam.

Includes three hundred new entities to make this edition even more comprehensive.

Incorporates hundreds of correlative MR and CT images so it's easier to confirm each diagnosis.

Uses a new design to make the book easier to read and navigate.

Features more rare and unusual images to help you identify less-often-seen images.

作者介绍:

目录:

[正常X线变异与可疑疾病鉴别诊断图谱_下载链接1](#)

标签

评论

[正常X线变异与可疑疾病鉴别诊断图谱_下载链接1](#)

书评

[正常X线变异与可疑疾病鉴别诊断图谱_下载链接1](#)